

# 2017-18 AOGS

# સંદર્ભ

Strong girls - Strong India  
**BULLETIN**


**AHMEDABAD  
OBSTETRICS AND  
GYNAECOLOGICAL SOCIETY**

NEWS LETTER | DECEMBER 2017



President  
**Dr. Hemant Bhatt**  
+91 98250 10940  
hemantbhat2012@yahoo.in

Hon. Secretary  
**Dr. Jignesh Deliwala**  
+91 98250 44819  
jadeliwala@yahoo.co.in



President - Elect  
**Dr. Jayprakash Shah**  
+91 94263 56198  
rajniji@yahoo.com

Vice President  
**Dr. Anil Mehta**  
+91 98253 16970  
dranilmehta@hotmail.com

Clinical Secretary (I/C)  
**Dr. Snehal Kale**  
+91 98240 95580  
kalesnehal@yahoo.com

Jt. Secretary  
**Dr. Tejas Dave**  
+91 98247 52776  
jignatejasdave@yahoo.co.in

Hon. Treasurer  
**Dr. Raj Iyengar**  
+91 98240 57054  
iyengarraj@rediffmail.com

#### Managing Committee Members

Dr. Akshay Shah | Dr. Hina Shah | Dr. Kamlesh Jagwani | Dr. Lata Trivedi | Dr. Mahesh Jariwala  
Dr. Munjal Pandya | Dr. Nita Thakre | Dr. Parth Shah | Dr. Sanjay Shah

Editors :  
Dr. Munjal Pandya  
Dr. Parth Shah

Ex-Officio  
Dr. Geetendra Sharma  
Dr. Rajal Thaker



Co-Opt. Members  
Dr. Dipesh Dholakia  
Dr. Alpesh Gandhi

Special Invitee  
Dr. Vilasben Mehta  
Dr. Tushar Shah  
Dr. Parul Kotdawala  
Dr. Rajesh Soneji  
Dr. Kamini Patel

### Ahmedabad Obstetrics & Gynaecological Society

2nd floor, Ahmedabad Medical Association Building, Ashram Road, Ahmedabad 380009  
Phone : 26586426 E-mail : ahmedabadobgynsoc@gmail.com | Website : ahmedabadobgyn.org

FIRST TIME IN ASIA  
**MATCHER SYSTEM**  
CERTIFICATION OF OWN  
SPERM/EGGS PREGNANCY IN IVF  
TO KEEP YOU IN SAFE HANDS



**IVF**  
SPECIALTY  
HOSPITALS



WINGS brings to you **Matcher - An electronic witnessing system** which assists in preventing misidentification of patients and their sperm/eggs and embryos.

**ADVANCED TECHNOLOGY AT WINGS**

- Time Lapse Incubator • IMSI • Micro Tesa

For thorough guidance on ways to avoid IVF failure,  
please call on **78787 77222 / 98250 50565**



**WINGS HOSPITAL:**  
2, Sumangalam Society, Opp. Drive-in Cinema, Thaltej, Ahmedabad.  
E.: enquiry@wingshospitals.com | W.: www.wingshospitals.com  
We don't conduct pre-natal sex determination test. It is a punishable offence.

Ahmedabad | Rajkot | Surat | Udaipur


HETARSH

# TEAM AOGS MESSAGE

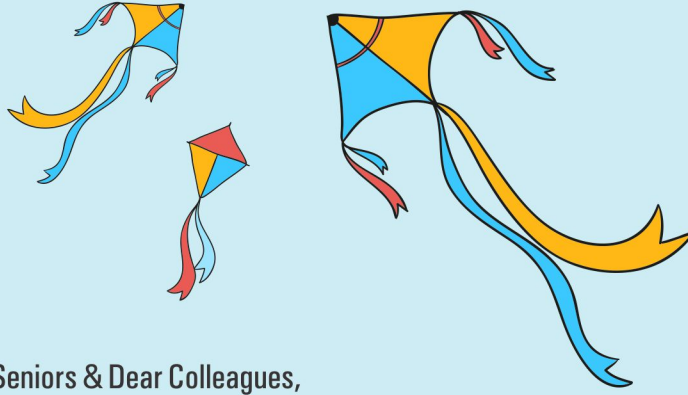
## TEAM AOGS MESSAGE



**Dr. Hemant Bhatt**  
President



**Dr. Jignesh Deliwala**  
Hon. Secretary



Respected Seniors & Dear Colleagues,

Recently we enjoyed two great festivals : one our Diwali & Bestu Varsh second our festival of Democracy : Gujarat elections. With all flavors in mind, we enjoyed thrilling moments in both festivals, particularly more in second festival! During those days, we also enjoyed wonderful academic seasons also : The conference on Critical care in Obstetrics & International conference of Ultrasonography. Both were great academic experiences for all attending delegates. There was an overwhelming response to both big conferences, although they were arranged back to back, due to tight schedule.

Now we are going to organize the SOGOG Annual Conference in partnership with Mehsana OB-GYN Society on 5th, 6th & 7th January. We expect an enthusiastic response from all our AOGS members We have carefully crafted the scientific programme for this conference, which can be very useful in our routine clinical practice. Our AOGS / SOGOG oration has been awarded to Dr.Dipak Limbachia. Kindly come & listen the SAGA of this great Endoscopist with his marvellous video presentation. The heart throb of delegates during AICOG-2017, OSMAN MIR is back. He is going to perform during our SOGOG Annual conference. Kindly come & enjoy the Saturday night of conference, on 6th January.

We are planning heritage walk of old city next month. We are also planning one academic programme at one of the old Havelis of walled city.

Thanks for electing SOGOG office bearers in truly democratic manner & thereby carving a new chapter for ever dynamic & united SOGOG.

Wishing you all the great year ahead in every respect & very happy UTTARAYAN.

### New Year Song

क्षणं प्रतिक्षणं यन्नवं नवम् । तच्च सुन्दरं सच तच्छिवम् ।

वर्षनूतनं ते शुभं मुदम् । उत्तरोत्तरं भवतु सिद्धिदम् ॥

*That which is ever new and fresh, that alone is Good, Real and Beautiful.  
May this New Year bring you greater and greater goodness, happiness and success.*

**CME : 13 - RHEUMATOLOGY-GYNECOLOGY  
DATE : 29 - 10 - 2017**




**CME ON AUB  
DATE : 05-11-2017 AT HOTEL HYATT VASTRAPUR**



# INTERNATIONAL CONFERENCE ON ULTRA-SOUND 2017

DATE : 24,25,26 - 11 - 2017



## ANOMALY SCREENING

A. Fetal Biometry    B. Targeted Fetal anomaly scan

### FETAL BIOMETRY

- Head**    BPD  
OFD/HC to Calculate HC
- Long Bones**    Femur Length  
Humerus Length
- Abdomen**    APTD  
TTD/AC to calculate AC (Ellipse)

## ANEUPLOIDY SCREENING

### SOFT MARKERS

- Head**    Nuchal Fold  
Lateral Ventricle
- Bones**    Femur  
Nasal Bone
- Abdomen**    Echogenic Bowel  
Pyelectesis
- CVS**    Echogenic Intracardiac Focus  
Aberrant Right Subclavian Artery

### RISK FIGURES

Risk Priori & Corrected Final Risk

## TARGETED FETAL ANOMALY SCANNING

### FETAL HEAD

*Brain :*

- Trans Ventricular Plain
- 2 Landmarks CSP Midline Falx
- 2 meas for biometry BPD OFD
- 2 meas for brain lateral ventricle ant post hom
- Trans Cerebellar Plain
- 2 landmarks CSP Midline
- 2 measurements TCD CM

*Face :*

- 2 Plains - Profile and PMT
- 2 Orbits 2 Lips 2 bony structure palate & mandible

### FETAL THORAX

- 2 organs Lungs & Heart
- 2 Views Transverse & sagittal
- 2 Transverse view 4ch & 3vv

### FETAL SPINE

- 2 Plains
- Transverse & Satittal / Coronal

### FETAL LIMBS

- 2 Upper limbs with 2 segments of upp. limb with 2 sets of bones
- 2 Lower limbs with 2 segments of limn with 2 sets of bones
- 2 Open hands with fingures
- 2 Feet for CTEV

### FETAL ABDOMEN

- 2 Tr. Plains at AC & level of umbilicus
- 2 Landmarks of AC middle 1/3 of port, vein & stomach
- 2 Umb. Art at tr.sec of cord & side of bladder
- 2 Kidneys for GUT evaluation Tr. section of kidneys and full bladder

### FETAL HEART

- 2 methods for situs clockwise/anticlockwise & Draw a Doll on Hand
- 2 Sections for situs & axis confirmation AC & 4CH view
- 2 Tr. Sections for cardiac evaluation 4CH & 3VV vies
- 2 Outflow Tract LVOT & RVOT
- 2 Arches Aortic Arch & Ductal Arch
- 2 Venous Channels RA Hammock view & LA for 2 Pul.veins
- 2 New modalities in fetal echo STIC & HD Flow

### FETAL GROWTH ASSESSMENT

2 Landmarks

- AC                       EFW

2 Vessel Doppler for Basic Evaluation

- Umbilical ART             Mid. Cere ART

2 Vessel Doppler for Decision Making

- Aortic Arch               Ductus Venosus

2 Uterine Art for Diagnosis of FGR

### FETAL ENVIRONMENT

Placenta :

- Location                       Thickness

Liquor Assessment :

- Qualitative                       Qualitative
- Eyeballing                      AFI
- Single Largest Pocke            MVP

Seen by : \_\_\_\_\_

Approved by : **Dr. Prashant Acharya**

# RULE OF 2

by Dr. Prashant Acharya

PARAS ADVANCED CENTRE FOR FETAL MEDICINE

www.drprashantacharya.com | www.parasfetalmedicine.com



## FETAL BIOMETRY - 5 POINTS

CRL  
BPD  
HC  
AC  
FL

## SOFT MARKER EVALUATION - 5 POINTS

Nuchal Translucency  
NB  
DV  
FMF angle  
TR

## EARLY FETAL ANOMALY SCANNING

### FETAL HEAD

Brain - 2 planes

- Trans ventricular plane - Butterfly sign
- Mid brain - Aqueduct plane

Face-2 planes

- Profile - Mid saggital view
- PMT
- 2 Orbits, 2 Lips, 2 bony structures (Palate and Mandible)

### FETAL THORAX

- 2 organs - Heart & Lungs
- 2 planes - 4 CH and 3VTV

### FETAL SPINE

2 planes

- Transverse & Saggital

### FETAL ABDOMEN

2 Transverse planes

- AC and Cord insertion at Umbilicus
- 2 Umbilical arteries at Side of bladder & cord insertion
- 2 kidneys
- 2 Sagittal plane - Mid sagittal for cord insertion and Left para sagittal plane for Lexus sign

### FETAL LIMB

- 2 Upper limbs, with 2 segments with 2 sets of bones
- 2 Lower limbs, with 2 segments with 2 sets of bones
- 2 open hands with fingers
- 2 feet with fingers and CTEV

### FETAL GESTATIONAL AGE

- 2 methods - LMP and CRL

### DOPPLER EXAMINATION

- DV
- 2 Uterine artery

### FETAL ENVIRONMENT

- Cervical length
- Placenta

### RISK ASSESSMENT

- Aneuploidy Risk : Risk a priori and Adjusted Final Risk
- Preterm birth risk prediction
- FGR and Preeclampsia risk prediction

Dr. Prashant Acharya MD, FICOG | Dr. Ashini Acharya MD

Seen by : \_\_\_\_\_

Approved by : Dr. Prashant Acharya

# A Review of Natural Galactagogue: Moringa Oleifera

Compiled By: Prof R.B Mishra, Ex. Director of Alternative Medicine, Rajasthan

## Introduction:

Breast-feeding provides optimal nutrition to newborns and infants, along with immune support and a host of lifelong health benefits to mother and child.

The purpose of this review is to describe the current evidence on herbal galactagogues.

Moringa leaves are a natural galactagogue - a substance that promotes or increases the flow of a mother's milk. It has been used since ancient times to boost breast milk supply as well as providing a source of nourishment for babies and mums alike.

Moringa oleifera is arguably the world's most nutritious plant and is also claimed to have a number of medicinal properties. While evidence has shown Moringa oleifera leaves help increase milk supply, we now also have clinical studies also backing up the claim. In fact, over the last 20 years a number of clinical studies have been conducted. In 2013, The Philippines Journal of Pediatrics published a report, which reviewed the findings of five scientific studies examining Moringa and its impact on breast milk supply.

### Risk factors for delayed onset of lactogenesis:

- Primiparity
- High body mass index
- Caesarean section
- Stress during labour
- Prolonged labour
- Mammary hypoplasia
- Use of analgesics during labour
- Family history of alcohol dependence and obesity (can inhibit the prolactin response required for milk production immediately postpartum)

## Effects on Lactation and Breast milk:

Mothers who delivered an infant before week 37 of gestation were randomized to receive commercial capsules containing Moringa oleifera leaves 250 mg (n = 31) or identical placebo capsules containing flour (n = 37) twice daily from day 3 postpartum. Mothers were given instruction on using a breast pump] then pumped their breasts every 4 hours and recorded the volume of milk produced from days 3 to 5. At baseline, control mothers collected a much lower volume of milk than mothers in the treatment group (87 vs 114 mL). Mothers in the treatment group had a greater increase in milk volume on day 4 (67% vs 42%) and day 5 (180% vs 38%) than mothers in the placebo group. Milk volumes on day 5 were 320 mL in the treatment group and 120 mL in the control group.

A study presented, 40 mothers with infants less than 37 weeks of gestation and producing less than 100 mL of milk on day 2 postpartum. Mothers were randomized to receive unspecified doses of domperidone, metoclopramide, Moringa oleifera powder, or placebo. Mothers used a breast pump to collect milk at unspecified intervals and serum prolactin was measured on days 3, 7 and 14 postpartum. Baseline milk production was equivalent among the groups. On days 7 and 14, milk volumes in all of the treatment groups were greater than in the placebo group.

## Moringa Proven to Increase Milk Supply:

Moringa oleifera leaves increase milk production on postpartum days 4 to 5 among mothers who were given natural galactagogues. Two randomized controlled also showed an increase in the weight of the infant when the mother took Moringa capsules. One clinical trial that was part of the larger study showed amazing results. In fact, it was published that breast milk volume increased 28-32% by day 3, 51-58% by day 4, and 152-176% by day 5.

Other studies showed that when mothers took 250-350 mg capsule twice per day, they had significantly increased volumes of milk production as well as increased baby weights.

Although more milk was produced by mothers receiving treatment than those receiving placebo (mean milk production was  $395.9 \pm 36.3$  mL in the treatment group compared to  $150.8 \pm 16.5$  mL in the control group on the last the day of treatment. In the latter study, women in the treatment group had significantly higher levels of prolactin in the 48 hours after delivery than women in the placebo group, and babies in the treatment group weighed significantly more than those in the placebo group at 4 months. Fenugreek seeds 3 times daily for 1 month did not show a significant difference in milk production compared with the placebo group.

Moringa oleifera is a multipurpose plant used in Ghana and most parts of Africa. Its high mineral, protein, and vitamins content.

## SAFETY:

have enabled its use as a nutraceutical and panacea for various diseases. This study aimed at measuring the micro- and macro-elements content of dried Moringa oleifera leaves using energy dispersive X-ray fluorescence spectroscopic (EDXRF) and assessing its toxicological effect in rats.

Acute toxicity (5000 mg/kg) and a subacute toxicity studies of the leaf (40 mg/kg to 1000 mg/kg) extract were conducted in rats. Blood samples were assessed for biochemical and haematological parameters. Results showed significant levels of thirty-five (35) elements (14 macroelements and 21 microelements) in M. oleifera extract. There were no observed overt adverse reactions in the acute and subacute studies. Moringa oleifera dried leaf extract, therefore, be reasonably safe for consumption. However, the consumption of Moringa oleifera leaves should not exceed a maximum of 70 grams per day to prevent cumulative toxicity of these essential elements over long periods.




## AOGS CONVEYS

*Hearty Congratulations*  
to

**Dr. M.C. Patel & Dr. Haresh Doshi**

**for being elected as Vice presidents of FOGSI for  
yr.2018 & 2019 respectively.**





Internationally Accepted Natural Galactogogue

# MORINGA

## PDF Lacto

(MORINGA OLEIFERA - 250 MG + ASPARAGUS RACEMOSUS - 500 MG)



*moringa-shatavari*

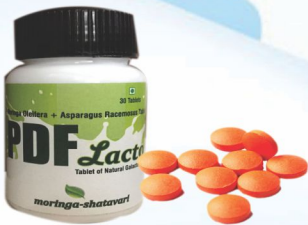### MORINGA EVIDENCE:

- 250 - 350 Mg twice per day, had significantly increased volumes of milk production as well as increased baby weight.
- Breast milk volume increased 28-32% by day 3, 51-58% by day 4, and 152-176% by day 5.

• Raguidin, P.F., et al. "Moringa oleifera as a Galactagogue." *Breastfeeding Medicine* 9.6 (2014): 323-324.  
 • Almirante, C., & Lim, C. (1996). Effectiveness of Natalac as Galactagogue. *Journal of Phil Med Assoc.*, 71(2), 272.

### TABLET

MORINGA+SHATAVARI



### POWDER

PROTEIN POWDER FORTIFIED WITH MORINGA+SHATAVARI



Extra Potency Micronized

Protein Mix

DHA, Fibres, EFAs, 16 Vitamins, 13 Minerals

Taste Fatigue Solution

Delicious  
2  
Flavour Pack  
Chocolate Flavour  
Kesar Elaichi Flavour



**Helios** **astris**  
SINCE 1985 Division

Developed by:  
Vivez Bioscience  
(Subsidiary of ORIGIN INDIA LLC, Atlanta, USA)  
Customer Care: 09723747213

For Detail Scientific Information  
Contact Medico Marketing Team:  
NIKITA - 079-40393351  
Email @ pmt.heliosastris@gmail.com

## OBITUARY



**DR. JYOTIBEN PARIKH**  
B.D.05.07.1928 Ex.D.18.12.2017

**DR. JYOTIBEN PARIKH**  
AOGS PAYS HOMAGE TO  
LEGENDARY SENIOR  
GYNAECOLOGIST DR. JYOTIBEN  
PARIKH. - SHE CONTRIBUTED  
ACTIVELY IN AOGS ACTIVITIES  
WITH GREAT DEXTERITY &  
ENTHUSIASM, ESPECIALLY  
DURING AICOG - 1963 & 1986  
ORGANISED AT AHMEDABAD

## ♥♥ Hearty Congratulations ♥♥



**DR. PRADYUMAN VAJA**

AOGS CONVEYS

**DR. PRADYUMAN VAJA**  
FOR BEING NOMINATED BY GOVT. OF INDIA  
AS A MEMBER OF CENTRAL  
SUPERVISORY BOARD UNDER PC-PNDT ACT.  
AN ACTIVE MEMBER OF AOGS  
SERVED AS JOINT DIRECTOR HEALTH IN  
GUJARAT GOVT.  
& DEDICATED TO SERVICE TO  
THE NATION UNDER NMO.



**DR. DIPAK LIMBACHIYA**  
M.D., D.G.O., Endoscopy Specialist  
Specialist in Advanced LAP Gynaec Surgeries &  
LAP Onco Gynaec Surgeries

EVA Hospital offers one step solution to all gynaecology and onco-gynaecology problems treated by exclusive laparoscopy.

We proudly announce another milestone of Dr. Dipak Limbachiya in the journey towards excellence that Dr. Dipak Limbachiya received prestigious award at Annual British Society for Gynaecological Endoscopy conference held at Hull, United Kingdom on 18 & 19 May 2017.

for presenting 3 videos,

1. Laparoscopic reversal of sterilization
2. Complications of laparoscopy: A decade of experience
3. A laparoscopic retrieval of a foreign body (broken surgical knife) from retroperitoneal space: An interesting case.

**Aesculap Einstein Vision2.0  
World Best  
3D Laparoscopic System**



**For video Watch**  
<http://bsge.org.uk/video-library/>



**Eva Womens Hospital & Endoscopy Center**  
Block-C, Neelkanth Park-II, Godha Camp Road, Shahibaug, Ahmedabad-380004  
Ph. 079-22682075, 22682217  
E: [info@evawomenshospital.com](mailto:info@evawomenshospital.com), W: [www.evawomenshospital.com](http://www.evawomenshospital.com)



The littlest feet make  
the biggest footprint  
in our hearts.

- High success rate in repeated IVF failure
- Pioneer in male infertility
- 7000+ Successful IVF Pregnancies

IUI

IVF

ICSI

Cryo preservation

Egg-Sperm & Embryo donation

TESA/PESA/MicroTESE/PGD/PGS

# HAT TRICK!

2016, 2017 Now **2018**



AHMEDABAD



- **Mumbai Institute**  
Mumbai: 3<sup>rd</sup>  
Western India: 6<sup>th</sup>
- **Delhi Institute**  
Delhi NCR: 7<sup>th</sup>  
Northern India: 10<sup>th</sup>

→ **Kolkata Institute**  
Emerging Institute  
in 2018

**THE TIMES OF INDIA**

(i3RCinsights Survey)

Dr. Falguni Bavishi M.D.  
Dr. Himanshu Bavishi M.D.



Dr. Janki Bavishi M.S.  
Dr. Parth Bavishi M.D.

Ahmedabad : Opp. Manjulal Muni. Garden, Next to Adani CNG & Gajarawala Flats, Paldi # Roads, Paldi, Ahmedabad-7  
Ph. +91-79-4040 4646 M. +91 98795 72298

GHATKOPAR	BORIVALI	ANDHERI	DADAR	THANE	VASHI	DELHI	SURAT	KOLKATA
2nd Floor, Vallabh Vihar, Next to Ramji Mandir, Nr. Rajawadi Signal, M. G. Road, Ghatkopar (E), Mumbai-77. Ph. 022-250 88888 M. +91-91672 04020	M. M. Medical Centre, Ankur, Nr. Marry Imm School, L.M. Road, Shivajinagar, Borivali (W), Mumbai-103. M. +91-91672 04019	Surya Hospital, Nr. Vallabh Park, Lalubhai Park Road, Ville Parle (W), Mumbai-49. M. +91-93204 59595	Amrit Medicare Clinic Pai House, GF, 601/E, Dr. Ambedkar Road, Matunga (E), Mumbai-19. M. +91-93204 59595	Bapat Urology Centre, Nr. Rupee Co.op. Bank, A.K. Vaidya Marg, Panch Pakhadi, Thane (W) - 400602. M. +91-91672 04018	Apollo Clinic, The Emerald, Sector 12, B/s. Neel Siddhi Towers, Vashi, Navi Mumbai-703 M. +91-91672 04018	Bavishi Bhagat Fertility Institute Bhagat Chandra Hospital, RZ-F 1/1, Mahavir Enclave, Nr. Dwarka Palam Flyover, Delhi - 45. M. +91-93126 30134	Bavishi Fertility Institute 901-902, 9th Floor, Param Doctor House, Lal Darwaja, Station Road, Surat. M. +91-98795 72247	Bavishi Pratiksha Fertility Institute Moore Heights, 93, Manik Bandopadhyay Sarani , Nr. Malancha Cinema, Tolly Gunj, Kolkata-700040 Ph. 033-4065 1000 M. +91-90739 30307

Toll Free No. : 1800 233 3434 | E-mail : drbavishi@ivfclinic.com | Website : www.ivfclinic.com